

# The *Mysterious* Coronary Ligaments

By Ben E. Benjamin



Illustrations provided by Putz/Pabst: Sobotta, *Atlas der Anatomie des Menschen*, 22nd edition  
© 2006 Elsevier GmbH, Urban & Fischer München

**D**espite their name, the coronary ligaments have nothing to do with a heart attack. These little-known ligaments are thin, flexible, wormlike structures located at the medial and lateral aspects of the knee. Their name is derived from the Latin word *corona*, meaning crown, and refers to their crown-like shape (see Figure 1). They are responsible for limiting rotation of the knee and for stabilizing the menisci—the thick, spongy, half moon-shaped cushions that act as shock absorbers between the tibia and femur. (Note that although the menisci are commonly referred to as cartilage, this type of cartilage is distinctly different from that of the Teflon-like articular cartilage that lines the articular surfaces of the femur and tibia). The coronary ligaments anchor the menisci to the tibia, while allowing them to slide anteriorly and posteriorly.

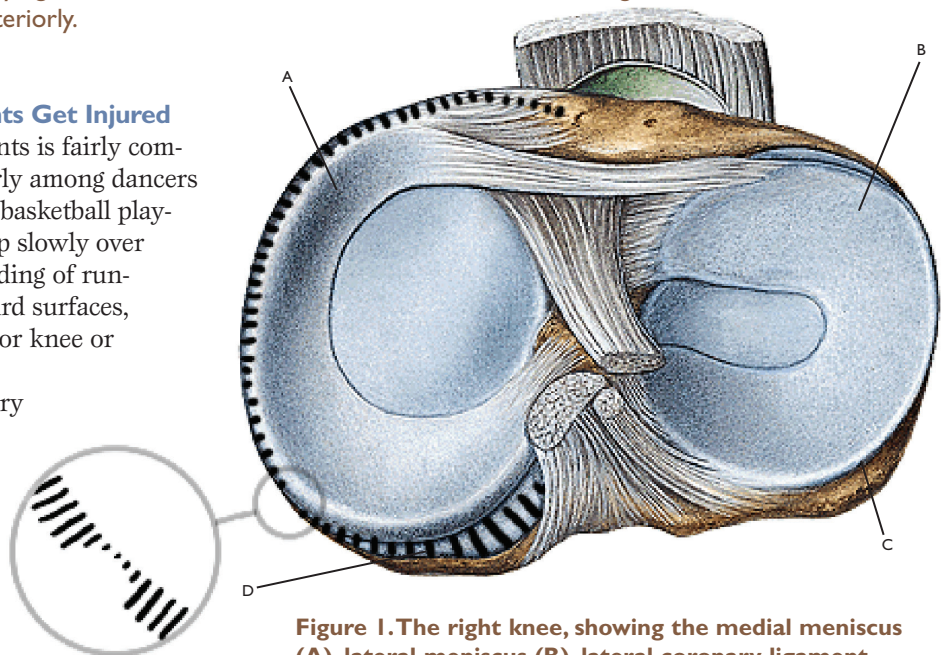
### How and Why These Ligaments Get Injured

Injury to the coronary ligaments is fairly common among athletes—particularly among dancers and tennis, football, soccer, and basketball players. Ligament strain may develop slowly over time through the constant pounding of running, dancing, or jumping on hard surfaces, particularly if the person has poor knee or foot alignment.

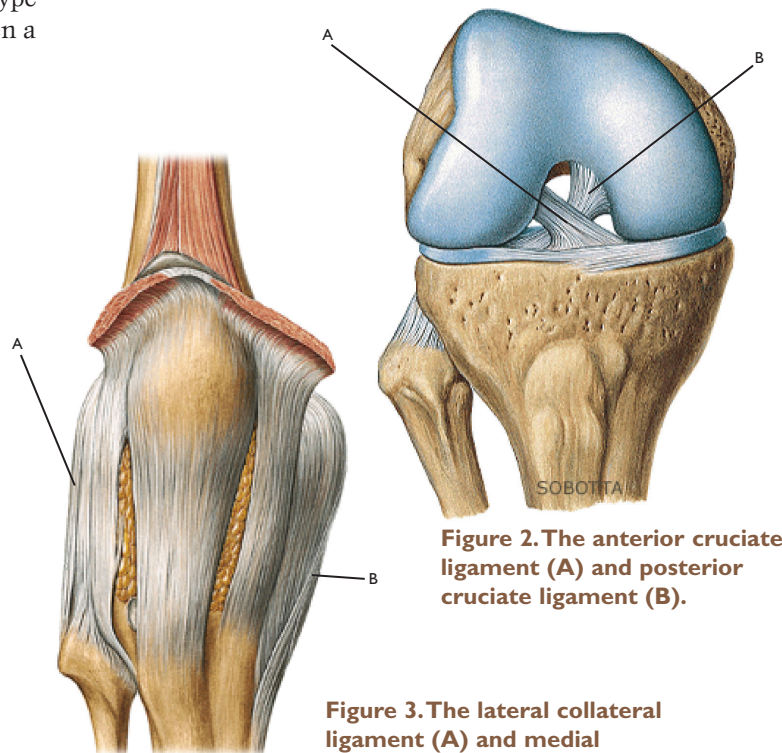
More often, however, the injury is sudden and dramatic. Typically, the precipitating incident is a sudden forceful medial or lateral twist of the knee that occurs while the foot remains stationary on the ground. (A lateral twist stresses the lateral coronary ligament, and a medial twist stresses the medial coronary ligament.) The knee isn't designed to twist in that way. This type of injury can happen in a basketball game when a player turns in midair for a jump shot and lands before fully completing the turn. Or it can happen when two soccer players kick a ball simultaneously, forcefully rotating their feet medially or laterally.

Pain caused by a coronary ligament injury can be sharp with sudden movement, but more often it is dull and achy. The pain is felt either laterally or medially and slightly anteriorly. When the injury is severe, there is swelling in the knee joint, making it difficult to fully bend or straighten the knee.

Coronary ligament injuries are particularly frequent among people who have lax cruciate and collateral ligaments. The cruciate ligaments are located in the center of the knee (see Figure 2). They stabilize the knee in anterior and posterior motions and limit the range of movement in these directions. The medial and lateral collateral ligaments (see Figure 3) stabilize the knee in side-to-side motions. When one or both sets of these ligaments are loose—either from a



**Figure 1.** The right knee, showing the medial meniscus (A), lateral meniscus (B), lateral coronary ligament (C), and medial coronary ligament (D). The medial coronary ligament is highlighted here and shows a tear at the anterior portion.



**Figure 2.** The anterior cruciate ligament (A) and posterior cruciate ligament (B).

**Figure 3.** The lateral collateral ligament (A) and medial collateral ligament (B).

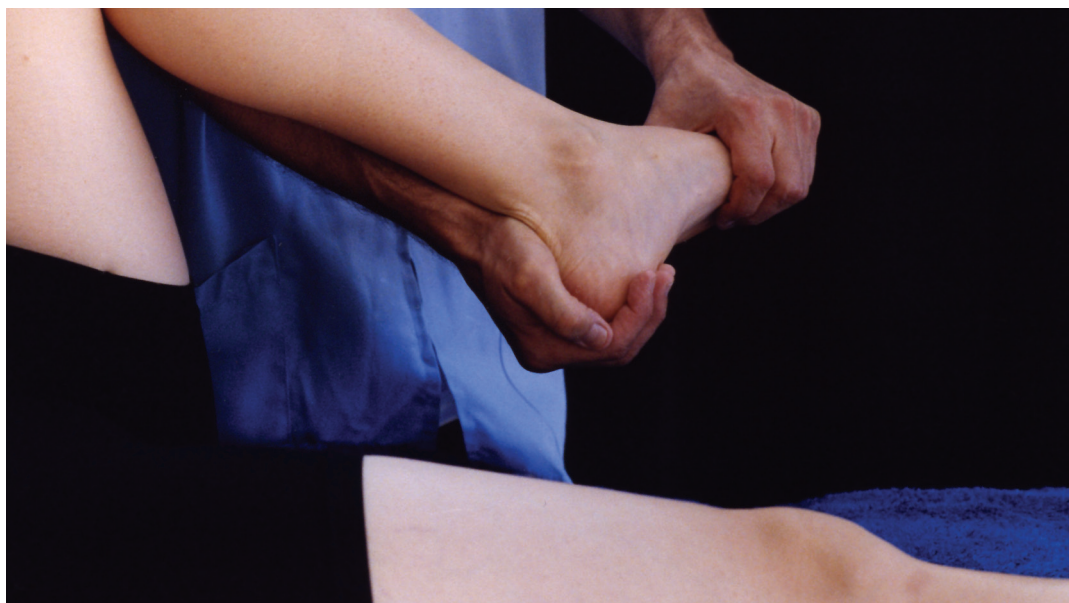

prior trauma or as a result of hereditary factors—the knee literally wobbles around when placed under stress through physical activity. This precondition makes it very likely that vigorous athletic activities involving turning and cutting movements will strain or tear the coronary ligaments.

Coronary ligament sprains frequently occur in conjunction with a more serious injury—a tear of the meniscus, commonly referred to as a torn cartilage. When the meniscus is torn, the knee periodically gives way, generally locking in a bent position, and becomes swollen. Often a coronary ligament is torn without damage to the meniscus, but if this injury goes untreated it can lead to instability and a subsequent meniscus tear, which usually requires surgery. Another adjacent structure that is vulnerable to injury is the medial collateral ligament. This ligament is contiguous with the medial coronary ligament, and it's common for these two structures to be injured simultaneously.

buckling and a feeling of weakness with pain and/or swelling that persists for several days or weeks. In other cases, however, the onset cannot be traced to a specific incident. The client may report constant pain that is intensified by walking just a few blocks, or else the pain may commence only after three or four miles of running or forty-five minutes of a vigorous sport.

The best way to reliably identify injuries to the coronary ligaments is to perform precise orthopedic assessment tests that isolate these structures. Pain felt on passive lateral rotation



## Injury Verification

The coronary ligaments are not clearly described

in most anatomy texts, and as a result most massage therapists and other health professionals are unaware of their significance. Injuries to these ligaments are often confused with injuries to other parts of the knee. For instance, an injury to the medial coronary ligament may be misidentified as a meniscus tear or a medial collateral ligament injury. An injury to the lateral coronary ligament may be misidentified as a strain of the iliotibial band (ITB) at the lateral attachment to the knee (which is located just a half-inch away).

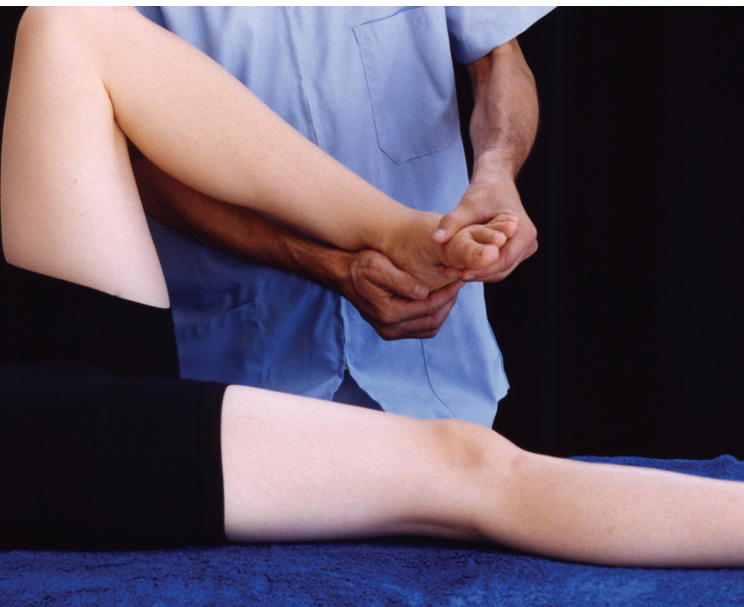Making assessment even more difficult is the range of different symptom profiles that coronary ligament injuries can cause. In some instances, the origin of the injury is obvious—there is a sudden trauma in which the knee twists while the foot remains stationary (as previously described). This is followed by

## Test 1. Passive lateral rotation

of the knee indicates a medial coronary ligament injury, and pain on passive medial rotation indicates a lateral coronary ligament injury.

**Test 1.** Passive lateral rotation (stresses the medial coronary ligament).

Standing at the client's knee while facing in a footward direction, lift the leg in the air so that it is bent at about a 90° angle. Place your medial hand on the lateral portion of the heel, cradling and supporting the knee with your forearm, and place your lateral hand on the medial aspect of the forefoot. Laterally rotate the foot to the end of its range while keeping it in dorsiflexion. If there is no discomfort or pain, give it a little extra rotation pressure. If the medial coronary ligament is injured, there will be pain at the anterior-medial aspect of the knee just on top of the tibia. →



**Test 2. Passive medial rotation**

**Test 2.** Passive medial rotation (stresses the lateral coronary ligament).

Standing in the same position as for passive lateral rotation (see above), switch your hands so that your medial hand is on the medial aspect of the heel and your lateral hand is on the lateral forefoot. Now, medially rotate the foot to the end of its range, keeping the foot in dorsiflexion. If this causes no pain or discomfort, give it a slight overpressure.

Note: when performing these test motions, be careful not to twist the ankle. A client will often say, “That hurts!” without specifying exactly what hurts. You may assume it’s the knee, but the client may be referring to the ankle. So be sure to check to see where the client feels the pain from each test.

### Treatment Options

The first step is to be sure that the client has seen an orthopedic physician to check for a tear in the meniscus. Once a meniscus tear has been ruled out, the treatment options will depend on the severity and location of the injury.

### Self-Treatment

Mild coronary ligament injuries often resolve on their own after a period of rest that includes some quadriceps-strengthening exercises—provided that the person avoids any activities that cause pain.

It’s important to watch for involuntary collapsing of the leg or locking of the knee, which would indicate an injury to the meniscus. If this begins to happen, send the client back to the doctor.

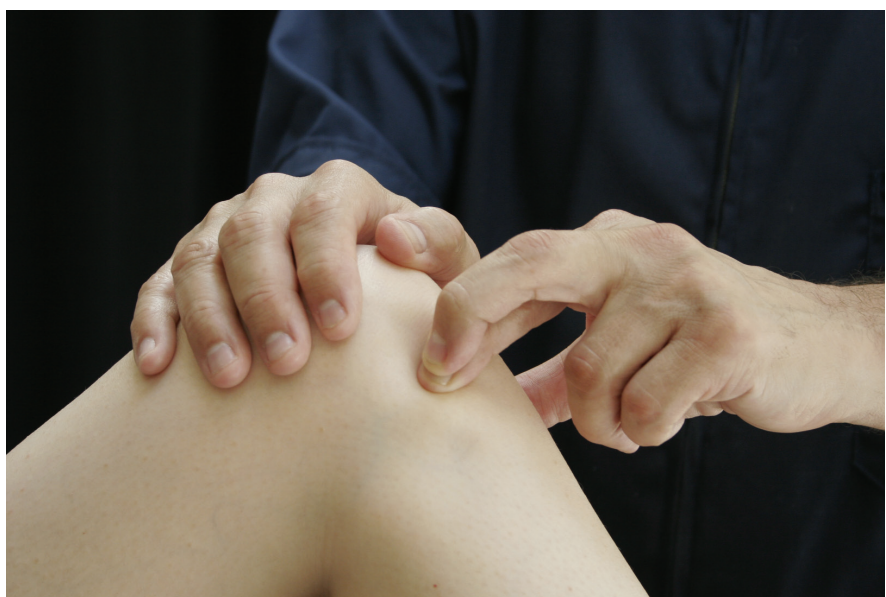### Friction Therapy

This hands-on treatment is effective only when the lesion is located in the anterior portion of the ligament. In these cases, the client generally feels pain at the anterior-medial or anterior-lateral edge of the tibial condyle, and one of those areas is tender on palpation. If the client experiences pain near the posterior edge of the tibial condyle, this suggests that the injured portion of the ligament cannot be accessed manually.

The techniques described here require a highly skilled action, so follow these instructions as precisely as you can.

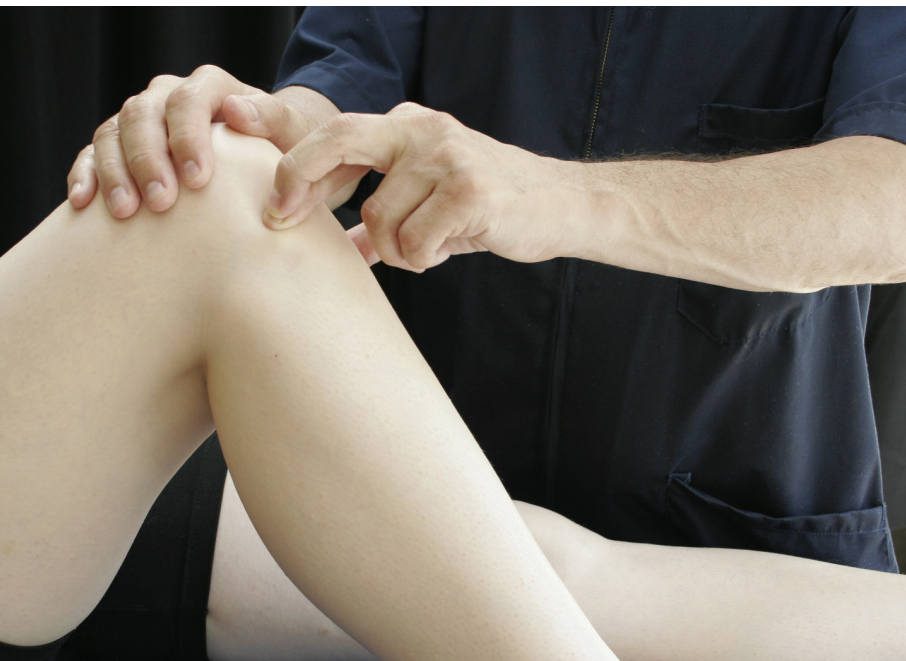#### Friction of the medial coronary ligament.

Stand at the side of the table near the knee you’ll be working on. Have the client’s leg bent at a 90° angle with the foot on the table. Now turn the foot laterally; this makes the ligament more accessible. Stabilize the leg by placing your headward hand on top of the knee with a downward pressure. Place the index finger of your footward hand on the medial tibial shelf with the middle finger on top of it for support. Friction toward or away from you, while pressing very firmly down onto the tibial shelf, for five or six minutes. Be sure to bring the client’s →



**Friction of the medial coronary ligament.**





**Friction of the lateral coronary ligament.**

skin with you as you move; don't slide over the skin. Then take a rest and do it again.

**Friction of the lateral coronary ligament.** Stand on the side of the table opposite the knee you'll be working on. Bend the client's leg to a 90° angle with the foot on the table, and then turn it medially. Stabilize the leg by placing your headward hand on top of the knee. Now reach across the table and place the index finger of your footward hand on the lateral tibial shelf, with the middle finger on top of it for support. Friction toward or away from you, while pressing firmly down onto the tibial shelf, for five or six minutes. Be sure to bring the skin with you

### Guidelines for Friction Therapy

**H**ere are some guidelines for effective application of friction therapy.

**Options for hand positioning.** If you're using your index finger to perform the friction, place your middle finger on top for reinforcement and wrap your thumb medially around the knee in a gripping action to offer an opposing force. Some therapists prefer to use the middle finger to friction. In that case, the middle finger can be reinforced by the index finger of the other hand. Other practitioners are more comfortable using the tip of their thumb. Experiment to find out which position is most comfortable for you.

**Applying pressure appropriately.** Be sure that the work involved in doing these techniques is shared by the muscles of your forearm, hand, and shoulder, or you will end up injuring yourself. While maintaining a downward pressure with your fingers and hand, move your entire arm—not just your fingers—to perform the friction.

Apply pressure in one direction only (either toward you or away from you) so you give yourself and your client a momentary rest with each stroke. After two or three minutes, switch the direction in which you apply the pressure. Then, after five or six minutes, take a break and repeat

the same procedure. Doing it in this way makes it less likely that you will need friction of the ligaments and tendons of *your* wrist and hand when you're finished helping the client.

Begin by using relatively little pressure and increase the pressure very gradually so that the client feels the least possible discomfort. As you work, the tissues will become slightly numb and less sensitive to the touch.

**Massage.** After you've performed friction therapy for ten to twelve minutes, massage all the surrounding tissues to increase the circulation in these areas as much as possible. I suggest working on the thigh, shin, calf, and buttock. Also massage the other leg, since it is probably under extra stress from compensating for the injured leg.

**Frequency and duration of treatment.** In my experience, friction therapy for a coronary ligament injury generally takes between four and eight weeks—depending on the seriousness of the injury and the general health of the client. Start by having the client come for two or three sessions per week, with each session including ten to twelve minutes of frictioning. As the client improves, taper off the treatment to once a week, then twice a month.

as you move. Then take a rest and do it again.

### Exercise to Accompany Treatment

As with many other injuries, exercise therapy is an important adjunct to friction and massage therapy when you're treating the coronary ligaments. Advise the client to use a stationary bike for fifteen minutes each day to keep the ligament mobile. The bike should be kept in a low gear, requiring minimal effort.

### Prognosis

**W**ith appropriate treatment, the prognosis for clients with injured coronary ligaments is very good. I've worked with many individuals who have made a full recovery from these injuries. What's often missing for people is the essential first step toward recovery—

**With appropriate treatment, the prognosis for clients with injured coronary ligaments is very good.**

accurate identification of the injury. Because the coronary ligaments are not widely known, they are often overlooked as a source of knee pain. If you were unfamiliar with them before, then just by reading this article you've enhanced your ability to

help clients who have injured these structures. I hope that the anatomical details, assessment protocols, and treatment techniques you've learned have helped to take some of the mystery out of these common and commonly misunderstood injuries. **M&B**

*Ben E. Benjamin, PhD, holds a doctorate in education and sports medicine. He is senior vice president of strategic development for Cortiva Education and founder of the Muscular Therapy Institute. He has been in private practice for more than forty years and is the author of Listen to Your Pain, Are You Tense? and Exercise Without Injury and coauthor of The Ethics of Touch. He can be contacted at [bbenjamin@cortiva.com](mailto:bbenjamin@cortiva.com).*

